

Assessment of Acute Toxicity of Cobalt Tetrasulfophthalocyaninate by Intravenous Injection on Wistar Rats

V. V. Chrishtop,^{a@} V. I. Demidov,^a I. K. Tomilova,^a V. G. Nikonorova,^a I. A. Tarasuk,^b A. A. Botnar,^b A. S. Vashurin,^b and Yu. S. Marfin^b

^aIvanovo State Medical Academy of the Ministry of Healthcare of the Russian Federation, 153012 Ivanovo, Russia

^bIvanovo State University of Chemistry and Technology, 153000 Ivanovo, Russia

@Corresponding author E-mail: chrishtop@mail.ru

Increased number of oncologic diseases stipulates urgent need to create new highly effective anticancer drugs, while one of the important directions is the development and study of toxic properties of new macroheterocyclic compounds. The study was conducted on 70 outbred Wistar rats of both sexes. The article presents the results of determining the acute toxicity of cobalt tetrasulfophthalocyaninate by intravenous injection and microscopic picture of brain, myocardium, lungs, liver and kidneys when stained with hematoxylin and eosin. It was found that with a single intravenous injection in accordance with State Standard 12.1.007-76 cobalt tetrasulfophthalocyaninate was referred to the 3rd class of mild-toxic compounds. Half-lethal dose in intravenous injection was amounting to 22.6 mg/kg. Sexual differences in half-lethal dose were not revealed. Death of animals occurred in the first 5 minutes of the study from respiratory arrest. Typical changes of the myocardium detected during microscopic examination were the structural basis of acute heart failure with respiratory distress syndrome development, acute venous plephora of brain, liver, kidneys. One of the important links of thanatogenesis, apparently, was the combination of disseminated bronchospasm and acute changes in arterial link of heart vascular channel which caused terminal condition development in the form of pulmono-coronary shock.

Keywords: Cobalt tetrasulfophthalocyaninate, acute toxicity, bronchospasm.

Оценка острой токсичности тетрасульфотфалоцианината кобальта на крысах вистар при внутривенном введении

В. В. Криштоп,^{a@} В. И. Демидов,^a И. К. Томилова,^a В. Г. Никонорова,^a И. А. Тарасюк,^b А. А. Ботнар,^b А. С. Вашурин,^b Ю. С. Марфин^b

^aИвановская государственная медицинская академия Министерства здравоохранения Российской Федерации, 153012 Иваново, Россия

^bИвановский государственный химико-технологический университет, 153000 Иваново, Россия

@E-mail: chrishtop@mail.ru

Рост количества онкологических заболеваний определяет острую необходимость создания новых высокоэффективных противоопухолевых препаратов, при этом одним из важных направлений является разработка и изучение токсических свойств новых макрогетероциклических соединений. Исследование проведено на 70 аутбредных крысах Wistar обоего пола. В статье приведены результаты определения острой токсичности тетрасульфотфалоцианината кобальта при внутривенном пути введения и микроскопическая картина головного мозга, миокарда, легких, печени и почек при окраске гематоксилином и эозином. Установлено, что при однократном внутривенном введении в соответствии с ГОСТ 12.1.007–76 тетрасульфотфалоцианинат кобальта относится к третьему классу умеренно токсичных соединений. Полуметальная доза при внутривенном пути введения составляет 22.6 мг/кг. Половых различий в полуметальной дозе выявлено не было. Смерть животных наступала в первые 5 минут исследования от остановки дыхания. Выявленные в ходе микроскопического исследования характерные изменения миокарда являются структурной основой острой сердечной недостаточности с развитием респираторного дистресс-синдрома, острого венозного полнокровия головного мозга, печени, почек. Одним из важных звеньев танатогенеза, по-видимому, стало сочетание распространенного

бронхоспазма и острых изменений в артериальном звене сосудистого русла сердца, что обусловило развитие терминального состояния в виде пульмоно-коронарного шока.

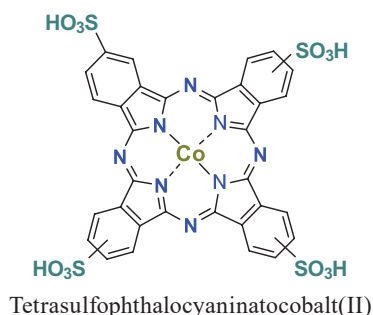
Ключевые слова: Тетрасульфопфталоцианинат кобальта, острая токсичность, бронхоспазм.

Introduction

The increase of oncological morbidity stipulated urgent necessity to develop new highly effective antitumor preparations. Nowadays significant amount of medicines with expressed oncostatic activity was produced. But the most part of these agents did not have definitely direct influence that's why they damaged both tumor cells and healthy tissues and organs. The evolution of malignant tumor cells' resistance towards traditional antitumor platinum-based drugs resulted in the necessity to study cytostatic properties of alternative transient metal-based compounds.^[1] Many reports pointed to the fact that biochemical and biophysical properties of cobalt compounds might be precisely settled to obtain new generations of antitumor drugs with clinically significant efficacy.^[2] But while studying toxic properties of these compounds one should take into consideration that these drugs were injected intravenously.^[3,4] Cobalt tetrasulfophthalocyaninate was one of the macroheterocyclic compounds with large spectrum of practical usage spheres (and owing to biomedical effects manifestation) namely potentially oncostatic and oxygen active forms' generator.^[5,6] Due to simplicity of its development and prevalence in chemical practice this compound was optimal as a model in studying toxic effects of cobalt(II) macroheterocyclic complexes. In this connection, the aim of this study was the investigation of acute toxicity of cobalt tetrasulfophthalocyaninate in intravenous injection in experimental animals.

Experimental

Cobalt tetrasulfophthalocyaninate was obtained and purified by well-known technique.^[7,8]



70 clinically healthy rats from vivarium (male and female) weighted 180–200 g were examined. The animals according to sanitary rules were under equal conditions of allowance and nutrition on vivarium standard diet.^[9–11] The rats were placed in quarantine for 2 weeks.

Acute toxicity was determined by one-time injection of the examined compound dissolved in 1 ml of 0.9 % sodium chloride into caudal vein by sterile syringe in 1 ml per one minute.

The batches were prepared by special procedure in order to maintain the correspondence of injected substance quantity to the doses of 8, 16, 24, 32, 40 mg/kg. Respectively, 5 groups of animals were formed according to conjugated analogues principle, in 14 rats in the group (7 male и 7 female) in each group, in order to determine possible sexual differences in sensitivity to the compound. The results of the experiments were estimated in 24 hours after the injection. Present status and number of the deceased animals were evaluated. The rats were under permanent control on the first day after the injection. General status, state of eyes and nose, pelage and skin texture, alterations in respiration, mobility, appetite, water consumption were examined per each day for the space of all observation period. Behavioral reactions on external irritants, skeletal muscles tonus, convulsions' presence and character, motion coordination change were estimated. Death time of the deceased rats was determined. Parts of brain, heart, lungs, liver and kidneys of the deceased animals were fixed in 10 % neutral formalin. After standard histological procedure the sections with thickness of 5–7 μm were stained by hematoxylin and eosin, brain sections were stained by Nissl method.

After examination the survived rats were turned out from the experiment by zoletil overdose. The survey was performed in accordance with the «Guide for preclinical investigations of medicinal preparations». Part 1 (2012)^[9,12] and with standards, adopted by the European Convention for Prevention of Vertebrate Animals, used for experimental and other scientific purposes.^[13] Acute toxic action parameters were calculated by Spearman-Kärber method by the formula: $LD_{50} = LD_{100} - (\Sigma(z*d)/n)$, where LD_{100} – dose which caused death of all animals; z – arithmetical mean of the number of animals which died after two adjacent doses; d – interval between two adjacent doses; n – number of animals in the group.^[14] Toxicity classification was carried out in accordance with State Standard 12.1.007–76.

Results and Discussion

Intoxication Clinical Findings

In intravenous injection of cobalt tetrasulfophthalocyaninate water solution in the dose of 8 mg/kg the following manifestations as retardation, adynamia, increased urine excretion and dyspnea were observed in rats. Within 30 minutes after the experiment completion general suppression was maintained.

After intravenous injection of cobalt tetrasulfophthalocyaninate in the dose of 16 mg/kg significant increase of dyspnea was observed, several rats were found in lateral position. In more mild cases the animals were not found in lateral position or changed this position rather quickly. Within an hour after the completion of the experiment general suppression was maintained in the animals and to the end of the first day of the observation survived rats did not differ from the intact ones.

After intravenous injection of cobalt tetrasulfophthalocyaninate in the doses of 24 mg/kg and 32 mg/kg clinical findings were as follows: significant locomotion suppression,

Table 1. Results of the examination of acute peroral toxicity of cobalt tetrasulphophthalocyaninate.

Sex of animal		Male					Female				
Dose, mg/kg		8	16	24	32	40	8	16	24	32	40
Number of animals in group/number of deceased animals		7/0	7/1	7/3	7/6	7/7	7/0	7/1	7/4	7/5	7/7
LD ₀ , mg/kg		8					8				
LD ₅₀ , mg/kg		22.6					22.6				
LD ₁₀₀ , mg/kg		40					40				

distinct decrease of the reaction on tactile, painful sound and light irritants. Dyspnea, anaemic color of mucosa membranes, tongue, claws, frequent intermittent hypopnea were revealed. The rats died from respiration arrest in the first 5 minutes of the examination.

In increase of the dose to 40 mg/kg on the background of cyanosis of visible mucosa and acrocyanosis short-term intense expiratory dyspnea preceded instantaneous asphyxia. Experimental animals were found in lateral position and died within 1-3 minutes from respiration arrest. The data upon animal lethality and the results of half-lethal dose (LD₅₀) are presented in Table 1.

Thus, in accordance with State Standard 12.1.007–76 it is referred to the third class of moderate toxic compounds (LD₅₀ mg/kg in intravenous injection > 2–20 mg/kg).

Results of Microscopic Examination of the Deceased Animals

Stasis of erythrocytes in capillaries, hyperemia of postcapillary link of hemomicrocirculatory channel, moderately expressed perivascular edema of nervous tissue were observed on brain microspecimens (Figure 1a.). Layer stratification was maintained in brain cortex frontal lobes and hemispherium cerebelli; pyramid neurons and Purkinje puriform cells were characterized by clear nucleus boundaries and Nissl cytoplasmatic granules, macroglial elements were distributed uniformly (Figure 1b).

Diffused hemostasis was visualized in hemomicrocirculatory channel in cardiac muscle microscopy (Figure 1c). Intramural arteries of right and left ventricles of cardiac muscle were found in spastic state with moderate stenosis of vascular lumen, reorientation of endothelial cells and manifested stroma perivascular edema (Figure 1d). The zones of cardiomyocytes' wavy deformation with irregular stain of contractile fibers were revealed in subendocardial areas (Figure 1e).

Acute venous hyperemia and pulmonary veins dilatation were revealed in lung parenchyma (Figure 2a). Disseminated hemostasis in hemomicrocirculatory channel vessels, manifested edema of interalveolar spaces were detected (Figure 2b). Spasm of small bronchi and bronchioles was determined (Figure 2c).

Moderately expressed hyperemia of hepatic veins and sinusoids of lobe centers according to acute muscat type was demonstrated in liver microscopic examination (Figure 2d), histoarchitectonics of hepatic lobes was maintained, single histiocytes and lymphocytes in stroma of portal channels were detected.

Moderately expressed acute venous hyperemia was observed in kidneys, glomerular capillary loops contained erythrocytes, capsule lumen was not dilated, nephrocytes of proximal and distal meandering canals were swollen with granular cytoplasm, lumen of canals was narrowed (Figure 2e).

Typical alterations of myocardium which were revealed within the microscopic examination were proved to be the structural grounds of acute heart failure with respiratory distress-syndrome development, acute venous plethora of brain, liver and kidneys. It was in accordance with the findings of many reports concerning neurotoxic,^[15] cardio- and hepatotoxic effects of cobalt water-soluble salts.^[16] Also several reports pointed to the influence of cobalt ions on reproductive function and malignant tumors induction.^[17,18] The combination of disseminated bronchospasm and acute alterations in arterial link of heart vascular channel seemed to be one of the important links of pathogenesis; it stipulated terminal state development in the form of pulmonary coronary shock and it was confirmed morphologically. Heart lesions in the form of multifocal myocytolysis with myofibrila degeneration and destructive inflammatory alterations of respiratory tract were revealed as the significant ones in the description of microscopic picture of acute toxicity of cobalt compounds in our study and in the reports of other researchers.^[19]

LD₅₀ of cobalt tetrasulphophthalocyaninate was proved to be rather high in comparison with other cobalt compounds. For example, LD₅₀ Co(III)-5,10,15,20-tetrakis(4-sulfonatophenyl)porphyrin was amounting to 334 mg/kg only,^[20] namely it almost 15 times less toxic. Different reports determined that peroral LD₅₀ for cobalt soluble compounds varied from 42.4 in cobalt chloride to 317 mg/kg of body weight in cobalt carbonate.^[21,22] LD₅₀ of insoluble compounds were more low, so LD₅₀ for tricobalt tetraoxide (insoluble compound) was amounting to 3672 mg/kg of body weight.^[23] On the other hand, LD₅₀ for phthalocyanines which were also structural analogues of the examined compound were not high as well. For instance, LD₅₀ for aluminium sulphophthalocyanine in intravenous injection was amounting to 1 g/kg^[24] and it 44 times lower than acute toxicity of the examined compound. High toxicity, on the one hand, was of great interest from the point of view of new compounds' development and well-known compounds modification, optimization of protection means for workers who were in contact with above mentioned compounds within technological processes and were exposed to technogenic catastrophe risk and industrial poisoning. On the other hand,

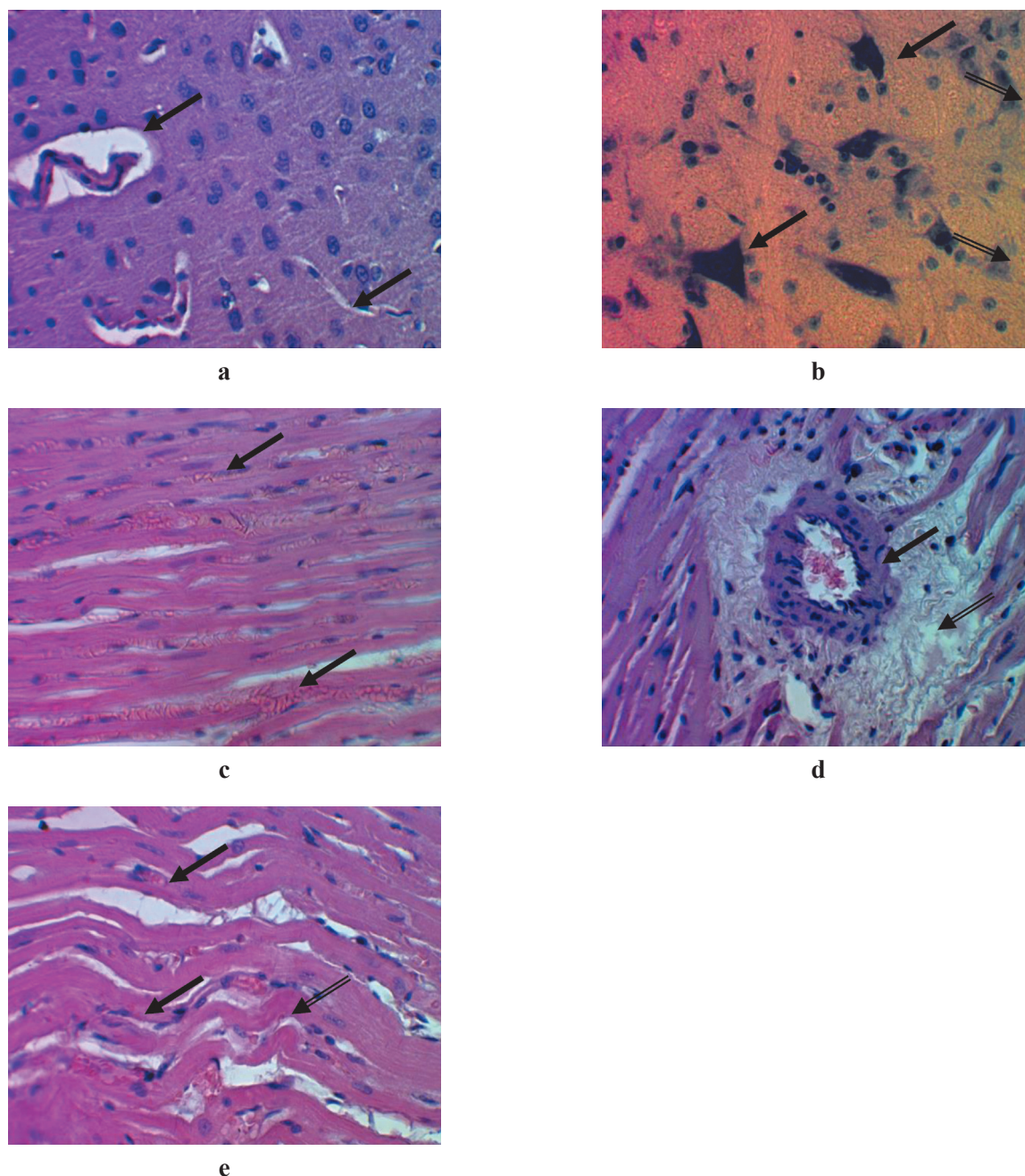


Figure 1. Cerebral morphological picture (a,b) and cardiac muscle (c,d,e) in rats deceased after cobalt tetrasulfophthalocyaninate injection. Magnification X 480.

a: Hemostasis, perivascular edema of white cortical substance of brain hemispheres. Stain by hematoxylin and eosin. **b:** Group of unaltered pyramidal neurons of brain hemisphere cortex (single arrow), macroglia cells – hypertrophic astrocyte, oligodendrogliaocyte (double arrow). Stain by toluidine blue by Nissl method. **c:** Stasis of erythrocytes in capillaries and venules, myocardium stroma edema. Stain by hematoxylin and eosin. **d:** Spasm of intramural artery of myocardium of left ventricle (single arrow), perivascular edema of myocardium stroma (double arrow). Stain by hematoxylin and eosin. **e:** Wavy deformation of myocardium contractile fibers (single arrow) with increased eosinophilia area (double arrow). Stain by hematoxylin and eosin.

the compound high toxicity which was revealed in the study was allowed to limit wide spectrum of potential biological usage of cobalt macroheterocyclic compounds in biomedical purposes such as diagnosis, tumor visualization,^[25] malignant tumors therapy,^[6] intervention into regulatory NO-ergic mechanisms,^[26] namely decrease of endogenic nitrites,^[27] etc.

Cobalt tetrasulfophthalocyaninate immobilization on polymer matrices might be the solution of these problems^[28] but it obviously would require additional toxicological investigations. As it was demonstrated that plasmachemical activation of polypropylene matrix resulted in macrocycle fixation to 80 %, in phthalocyanine fixation into siliconorganic matrix only 65 % of macrocycle was fixed.^[5,29,30]

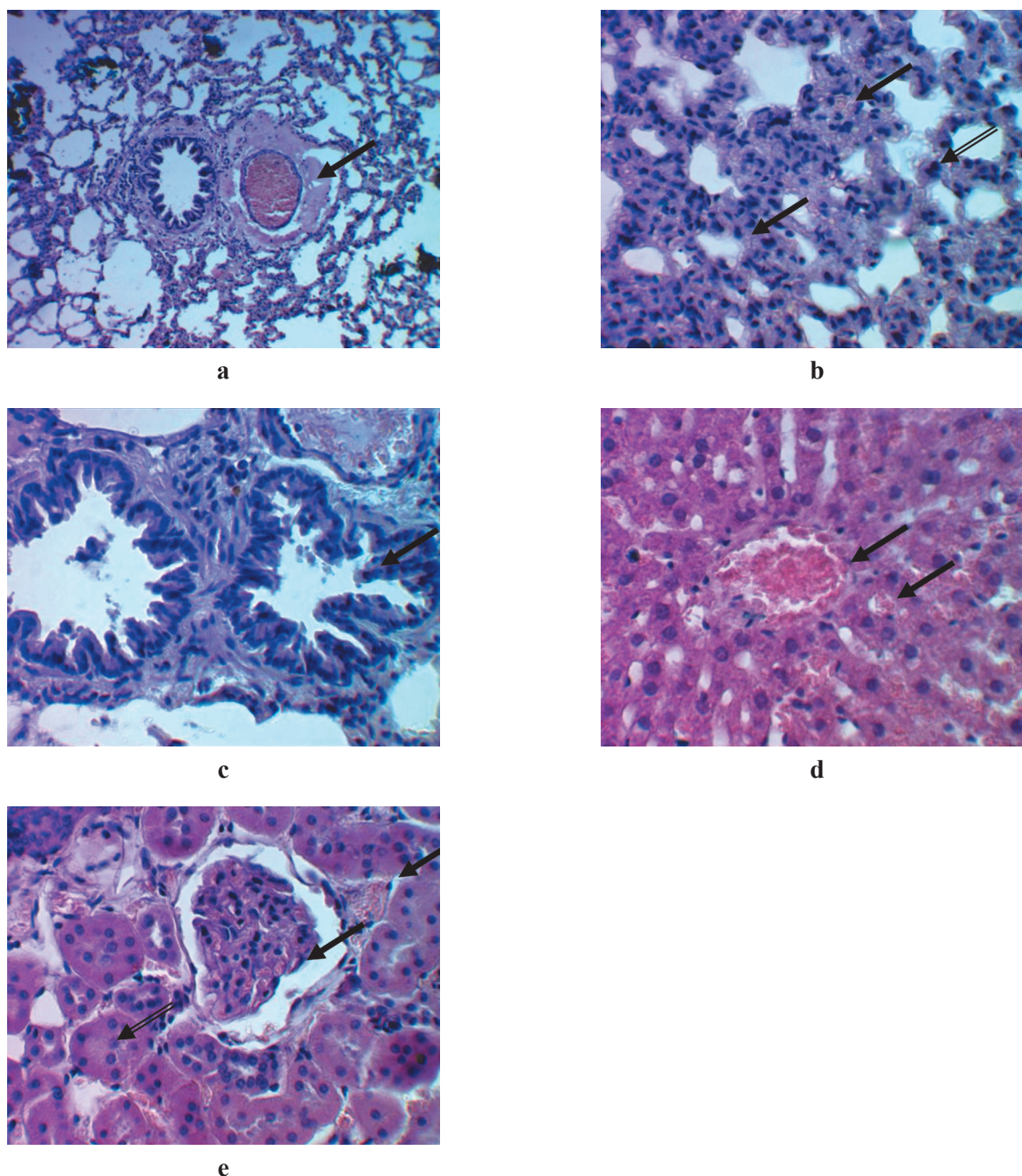


Figure 2. Morphological picture of lungs (**a,b,c**), liver (**d**) and kidneys (**e**) in rats which deceased after injection of cobalt tetrasulfophthalocyaninate. Stain by hematoxylin and eosin. Magnification X 480.

a: Plethoric dilated pulmonary vein with plasmorrhagia. **b:** Plethora, edema of interalveolar spaces (single arrow), onset of erythrodiapedesis into alveolar lumina (double arrow). **c:** Disseminated bronchospasm. **d:** Acute plethora of hepatic vein and sinusoids. **e:** Plethora of glomerule, interlobate arteries (single arrow). Protein dystrophy of nephrocytes, channels' lumen narrowing (double arrow).

Conclusion

Thus, the study of acute toxicity of cobalt tetrasulfophthalocyaninate in single injection demonstrated that this complex was a moderately toxic compound. LD_{50} in intravenous injection was amounting to 22.6 mg/kg. Sexual differences in LD_{50} were not revealed. Combination of disseminated bronchospasm and acute alterations in arterial link of heart vascular vessels seemed to be one of important pathogenesis links and it stipulated terminal

state development in the form of pulmonary coronary shock. These facts should be taken into consideration in dose selection for chronic toxicological investigations and for further usage of this compound in clinical practice.

Acknowledgements. The study was performed in the frames of the state task of the Ministry for Healthcare of the Russian Federation «Examination of biomedical effects of macroheterocyclic compounds with anticancerogenic activity for the development of new medicinal preparations».

References

- Vashurin A.S., Pukhovskaya S.G., Garasko E.V., Voronina A.A., Golubchikov O.A. *Macroheterocycles* **2014**, 7, 272–275.
- Munteanu C.R., Suntharalingam K. *Dalton Trans* **2015**, 44, 796–808.
- Kaplan M.A., Shubina A.M., Borgul O.V., Nikitina R.G. *Problems in Oncology [Вопросы онкологии]* **2010**, 56, 345–347 (in Russ.).
- Krishtop V.V., Pakhrova O.A., Kustov A.V., Khudyaeva I.S., Belykh D.V., Makarov V.V., Kruchin S.O., Berezin D.B. *Advances in Current Natural Sciences [Успехи современного естествознания]* **2017**, No. 3, 20–29 (in Russ.) (URL: <http://www.natural-sciences.ru/ru/article/view?id=36406>).
- Vashurin A.S., Voronina A.A., Pukhovskaya S.G., Kuzmin I.A., Kuzmichyova L.A., Golubchikov O.A. *Izv. Vyssh. Uchebn. Zaved. Khim. Khim. Tekhnol.* **2013**, 56(11), 74–78 (in Russ.).
- Gerasimova G.K., Yakubovskaya R.I., Pankratov A.A. *Russ. J. Gen. Chem.* **2015**, 85(1), 289.
- Weber J.H., Busch D.H. *Inorg. Chem.* **1965**, 4, 469.
- Yang Y.C., Ward R.J., Seiders R.P. *Inorg. Chem.* **1985**, 24, 1765.
- Rules of Laboratory Practice in the Russian Federation* (Order of the Ministry of Healthcare of the Russian Federation No 708n dated 23.08.2010) (in Russ.) [Правила лабораторной практики в Российской Федерации (Приказ Министерства здравоохранения Российской Федерации №708н от 23.08.2010)].
- Order of the Ministry of Health of the USSR No.1045-73 dated 04.06.1973 *Sanitary Rules for the Design, Equipment and Maintenance of Experimental Biological Clinics (vivariums)* (in Russ.) [Приказ Министерства здравоохранения СССР №1045-73 от 06.04.1973 Санитарные правила по устройству, оборудованию и содержанию экспериментально-биологических клиник (вивариев)].
- Order of the Ministry of Healthcare of the USSR No 1179 dated 10.10.1983 *On Affirmation of Nutrition Expenditures Standards for Laboratory Animals in Public Health Facilities* (in Russ.) [Приказ Министерства здравоохранения СССР №1179 от 10.10.1983 Об утверждении нормативов затрат кормов для лабораторных животных в учреждениях здравоохранения].
- Mironov A.N. *Guide for Preclinical Studies of Drugs*. Part I. Moscow: Grif i K, **2013**. 944 p. (in Russ.) [Миронов А.Н. Руководство по проведению доклинических исследований лекарственных средств. Ч. 1. М.: Гриф и К, **2013**. 944 с.].
- European Convention for the Protection of Vertebrate Animals Used for Experimental and Other Scientific Purposes (ETS 123). Strasbourg, **1986**.
- Glukhareva E.V. *Russ. J. Parasitology [Российский паразитологический журнал]* **2016**, 35(1), 114–118 (in Russ.).
- Litvinova S.A., Voronina T.A., Nerobkova L.N., Kutepova I.S., Avakyan G.G., Avakyan G.N. *Pharmacol. E. J.* **2019**, 5, 380–386.
- Liu Y.K., Xu H., Liu F., Tao R., Yin J. *Orthop. Surg.* **2010**, 2, 134–140.
- Pedigo N.G., George W.J., Anderson M.B. *Reprod. Toxicol.* **1988**, 2, 45–53.
- Pedigo N.G., Vernon M.W. *Reprod. Toxicol.* **1993**, 7, 111–116.
- Kim J.H., Gibb H.J., Howe P.D. *Cobalt and Inorganic Cobalt Compounds* (Concise International Chemical Assessment Document) **2006**, 16–17.
- Mc Guinn W.D., Baxter L., Pei L., Petrikovics I., Cannon E.P., Way J.L. *Fundam. Appl. Toxicol.* **1994**, 23, 76–80.
- FDRL Study No.8005D. Acute Oral LD50 Study of Cobalt Sulphate Lot No. S88336/A in Sprague-Dawley rats. Waverly, NY, Food and Drug Research Laboratories, Inc., **1984**.
- FDRL (1984b) Study of Cobalt (II) Carbonate Tech gr. CoCO₃, lot No. 030383 in Sprague-Dawley rats. Waverly, NY, Food and Drug Research Laboratories, Inc., **1984**, 12.
- Singh & Junnarkar. *Acute Oral Toxicity Study of Cobalt Oxide Tricobalttetraoxide in Sprague-Dawley Rats*. Waverly, NY, Food and Drug Research Laboratories, **1984**, 5.
- Torshina N.L. Preparation for Photodynamic Therapy for Malignant Tumors. Patent № RU 2 145 221 Cl.
- Volovetsky A.B., Sukhov V.S., Balalaeva I.V., Dudenkova V.V., Shilyagina N.Y., Feofanov A.V., Efremenko A.V., Grin M.A., Mironov A.F., Sivaev I.B., Bregadze V.I., Maslennikova A.V. *Int. J. Mol. Sci.* **2017**, 18, 2556.
- Pogorelova A.S., Makarov S.V., Ageeva E.S., Silagi-Dumitrescu R. *J. Phys. Chem.* **2009**, 83, 2250–2254.
- Singh P.P., Junnarkar A.Y. *Ind. J. Pharm.* **1991**, 23, 153–159.
- Vashurin A.S., Kuzmin I.A., Kuzmichyova L.A., Pukhovskaya S.G., Titova Yu.V., Titov V.A., Golubchikov O.A. *Russ. Khim. Zh.* **2014**, 58(5-6), 53–58 (in Russ.).
- Gong Y.G., Zhang T.F., Li M., Zhao Q.Y., He D., Xi N., Cheng J., Chen Y.L., Liu B. *Yao Xue Xue Bao* **2016**, 51, 425–33.
- Vashurin A.S., Marfin Yu.S., Tarasyuk I.A., Kuzmin I.A., Znoyko S.A., Goncharenko A.A., Romyantsev E.V. *Appl. Organomet. Chem.* **2018**, 32, 1–10.
- Tarasyuk I.A., Kuzmin I.A., Marfin Yu.M., Vashurin A.S., Voronina A.A., Romyantsev E.V. *Synth. Met.* **2016**, 217, 189–196.

Received 23.12.2019

Accepted 30.01.2020